

# Insights Into Chiropractic

*Discerning the true nature of an alternative health care method*

## The Forward Head Posture

### INTRODUCTION

Forward head posture is a clinical entity that has been identified by multiple authors(1-6) as a significant factor in a variety of musculoskeletal pain syndromes. Although some reports are essentially anecdotal,(1-3) several reports use sophisticated statistical analyses and healthy controls versus painful subjects to establish the forward head posture as a real clinical entity with significant musculoskeletal consequences.(4-6)

Unfortunately, the assessment of head posture in relation to the thorax and the subsequent assessment of the underlying skeletal geometry is a subject that has been largely neglected in clinical practice. In this article we will discuss the assessment of forward head posture and review a couple of methods commonly used by doctors of chiropractic for the reduction of this common postural displacement.

### POSTURAL ASSESSMENT

Normal postural alignment of the head over the thorax in the lateral view has been described as the vertical alignment of the external auditory meatus over the acromioclavicular joint.(2,3,7) This position can be assessed very simply with the use of a plumb line with the patient in the relaxed neutral position. Sometimes, examiners will employ the use of a Polaroid camera mounted to a leveled tripod and loaded with special film that has gridlines applied to the film to document the existence of the forward head posture.

Fortunately, a number of authors have assessed the repeatability of the relaxed neutral position

or "self-balance position"(8) with the use of bi-planer photography,(9) with the use of lateral cephalometric radiographs,(8) and on lateral cervical radiographs.(10) In each case, subjects were instructed to assume a neutral relaxed posture prior to assessment. In one of the studies, subjects were instructed to tilt the head forward and backward with decreasing amplitude until they reached the most relaxed position and then were instructed to look into the eyes of their own reflected image in a mirror placed two meters away.(8) In another study, the subjects were instructed to simply close their eyes and flex and extend the head twice and to come to their most neutral relaxed position-hold this position still-and then open their eyes.(10)

In all of these studies the test subjects returned to the same self-balance position when tested over time periods ranging from one minute(9), two minutes(9), one hour(8), one week(9), and twelve weeks,(10) thus establishing the repeatability of the self-balance position as a stable posture over time. Using these methods, or slightly modified versions of these methods, has resulted in the establishment of the forward head posture as a condition with the musculoskeletal tissues paying the price of increased pain and alterations in overall spinal mobility.(4-6)

### ASSESSMENT OF SKELETAL GEOMETRY OF THE SPINE

At least two simple methods exist that determine various spinal and head positions on lateral radiographs. The first, developed by the dental and orthodontia communities measures the relative

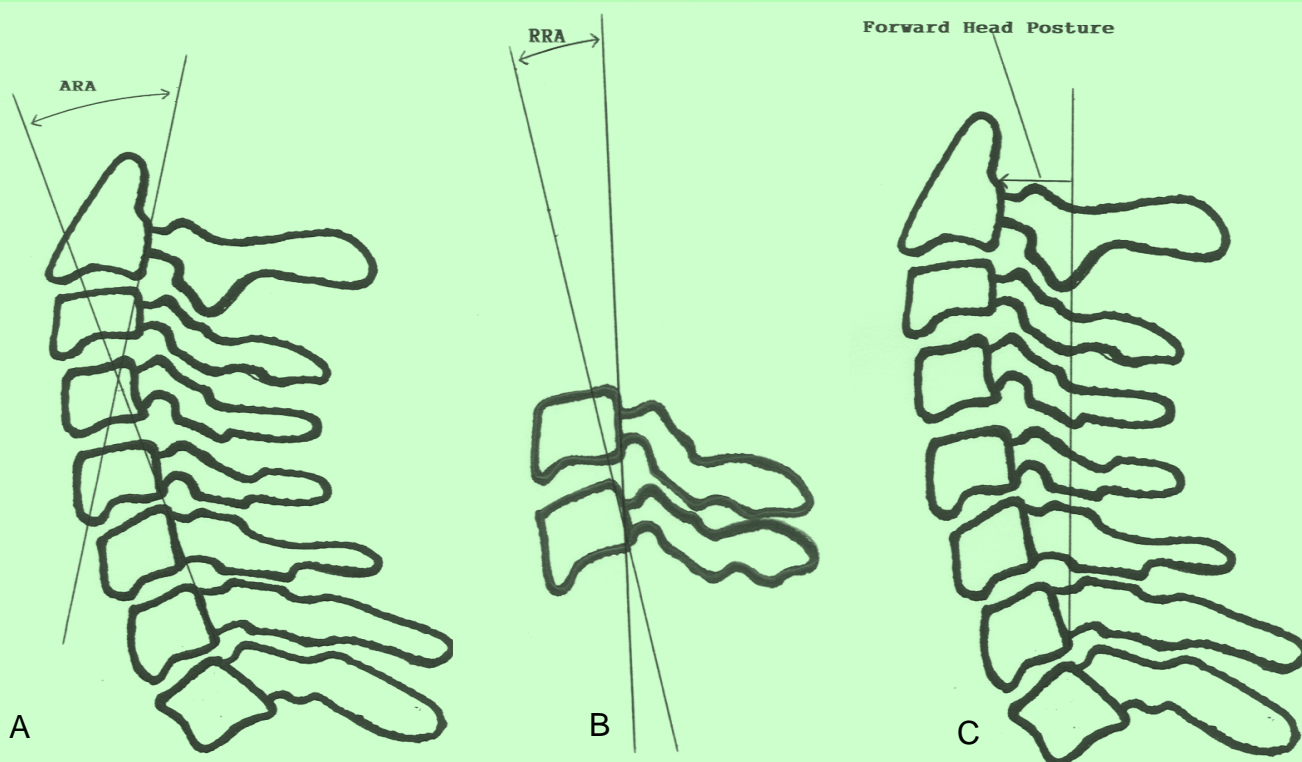


Figure 1. A) Absolute rotation angle (ARA) of overall lordosis magnitude. B) Relative rotation angle (RRA) or magnitude of intersegmental angle. C) Linear measure of forward displacement of head relative to upper dorsal spine.

positions of the skull, axis vertebra, and a combination of a line connecting the posterior tip of the odontoid process of C2 and the postero-inferior body margin of C4 to true vertical and horizontal lines determined from lateral cephalometric radiographs.(8) Although highly reliable and reproducible, this method has less relevance to medical and chiropractic practice than the next method to be described.

Jackson et al.(11) describe a method of determining the relative position of adjacent vertebrae on neutral lateral cervical radiographs by constructing lines drawn across the posterior vertebral body margins of C2 through C7. They termed the measurement of the angle of intersection of such lines as relative rotation angles. Overall cervical lordosis is determined by measuring the angle of intersection between lines drawn across the posterior vertebral body margins of C2 and C7. Jackson et al. termed this measure of overall cervical lordosis as the absolute rotation angle of the cervical spine. Finally, Jackson et al. describe a method of

measuring forward head posture on lateral cervical radiographs by constructing a vertical line superiorly from the postero-inferior corner of C7 and measuring the perpendicular distance from this line to the posterosuperior portion of the vertebral body of C2. These measures are illustrated in Figure 1 and represent a repeatable and reliable method to quantify the cervical lordosis and any amount of forward head posture that exists in your patients and is demonstrated on weight bearing lateral cervical radiographs.

#### WHAT IS NORMAL?

Already described above, normal postural alignment when performing visual inspection exists when the external auditory meatus lines up directly over the acromioclavicular joint. On lateral cervical radiographs several authors have described the attributes of normal skeletal geometry of the spine in patients without a history of neck pain(12) and in a group of patients without cervicocranial symptoms selected using a specified biomechanical criteria.(13)

Gore et al.(12) described the geometric configuration of the cervical spine in 200 asymptomatic people ranging in age from 20 to 60 years of age. When comparing the angle of intersection of lines drawn along the posterior vertebral body margins of C2 and C7 (as described above) they found the average degree of overall cervical lordosis was 21 degrees.

Similarly, Harrison et al.(13) found the overall average degree of lordosis between C2 and C7 in their 252 asymptomatic subjects selected using biomechanical criteria to be 34 degrees. This establishes a normal average range of lordosis between C2 and C7 of 21-34 degrees in so-called "normal subjects." When assessing the magnitude of forward head posture, Harrison et al.(13) found an average of about 15 millimeters of forward displacement of the head in relation to the thorax using the measurement described above and depicted in Figure 1C.

Finally, Harrison et al.(13) found the average range of relative rotation angles for the lower cervical spine (i.e. C3-C4 through C6-C7) to vary between 6.26 and 7.18 degrees for the geometric position of adjacent vertebrae. The average relative rotation angle found for C2-C3 was 7.59 degrees and was explained as being larger overall in comparison to the other relative rotation angles (i.e. C3-C4 through C6-C7) because C2 is anatomically a larger vertebrae than the remaining lower cervical vertebrae and would naturally make up a larger portion of a circular lordosis in the cervical spine.

The values presented above can now serve as standards against which to compare patients and to assess outcome for interventions designed to reduce the clinical entity of the forward head posture.

#### CLINICAL INTERVENTIONS FOR THE FORWARD HEAD POSTURE

Two studies demonstrate interventions that are often provided by doctors of chiropractic that have been shown to reduce the magnitude of the

forward head posture. Pearson and Walmsley(14) described their findings in terms reduction of forward head posture assessed externally (i.e. without x-ray examination) in a group of 30 subjects who performed a total of three sets of 10 repetitions of neck retraction exercises. In this form of exercise, subjects are instructed to pull ". . . the head and neck posteriorly into a position in which the head is aligned more directly over the thorax, while the head and eyes remain level."(14) They found that after performing the second set of exercise the subjects' neutral resting posture demonstrated a small but statistically significant ( $p<0.05$ ) reduction in forward head posture that averaged approximately 4mm.

Additionally, Harrison et al.(10) found an average overall improvement in cervical lordosis of 13.2 degrees measured between C2 and C7 on post-treatment radiographs and an average of 9.8mm reduction in forward head posture following a regimen of twelve weeks of maximum tolerance cervical extension traction in a retrospective sample of 35 subjects. These results were compared to a control group who received no intervention over a similar twelve week period whose cervical alignment and posture showed no change.

These two studies, although preliminary in nature, demonstrate two methods that are routinely used by chiropractic physicians in their efforts to reduce the effects of the forward head posture syndrome. One of these methods is "passive" (extension traction) while the other involves the active participation of the patient (exercise). One can only speculate what synergistic effect these two methods might have if used together, and chiropractic physicians that routinely use these two methods in clinical practice have empirically observed consistent results in the reduction of the forward head posture with loss of or reduction in cervical lordosis. A controlled clinical trial would be necessary to confirm this clinical observation.

## CONCLUSION

The forward head posture is an abnormality of posture that is routinely observed in subjects with a wide variety of musculoskeletal complaints. Clinicians and researchers have devised reliable methods to assess both the posture and the skeletal alignment of the spine and skull of patients with such abnormalities. Methods exist that have been shown to reduce the magnitude of the forward head posture that are commonly used by doctors of chiropractic. For those interested in the care and management of patients with musculoskeletal complaints secondary to the forward head posture, chiropractic referral seems a logical consequence of these findings.

## REFERENCES

1. Mennell JM. The musculoskeletal system-differential diagnosis from symptoms and physical signs. Gaithersburg, Maryland: Aspen Publishers, Inc.; 1992. pp126-33.
2. Donatelli R, Wooden M. Orthopaedic physical therapy. New York: Churchill Livingstone Inc.; 1989.
3. Cailliet R. Soft tissue pain and disability. Philadelphia: FA Davis Co.; 1977.
4. Haughie LJ, Fiebert IM, Roach KE. Relationship of forward head posture and cervical backward bending to neck pain. *J Manual manipulative Ther* 1995;3:91-7
5. Greenfield B, Catlin PA, Coats PW, et al. Posture in patients with shoulder overuse injuries and healthy individuals. *JOSPT* 1995;21:287-95.
6. Griegel-Morris P, Larson K, Mueller-Klaus K, Oatis CA. Incidence of common postural abnormalities in the cervical shoulder, and thoracic regions and their association with pain in two age groups of healthy subjects. *Phys Ther* 1992;72:425-31.
7. Lee D. Principles and practices of muscle energy and functional techniques. In: Grieve GP (ed) *Modern manual therapy of the vertebral column*. New York: Churchill Livingstone; 1986.
8. Sandham A. Repeatability of head posture recordings from lateral cephalometric radiographs. *British J Orthodontics* 1988;15:157-62.
9. Refshauge K, Goodsell M, Lee M. Consistency of cervical and cervicothoracic posture in standing. *Australian Physiotherapy* 1994;40:235-9.
10. Harrison DD, Jackson BL, Troyanovich S, et al. The efficacy of cervical extension-compression traction combined with diversified manipulation and drop table adjustments in the rehabilitation of cervical lordosis: A pilot study. *J Manipulative Physiol Ther* 1994;17:454-64.
11. Jackson BL, Harrison DD, Robertson GA, Barker WF. Chiropractic biophysics lateral cervical film analysis reliability. *J Manipulative Physiol Ther* 1993;16:384-91.
12. Gore DR, Sepic SB, Gardner GM. Roentgenographic findings of the cervical spine in asymptomatic people. *Spine* 1986;6:521-4.
13. Harrison DD, Janik TJ, Troyanovich SJ, Holland B. Comparisons of lordotic cervical spine curvatures to a theoretical ideal model of the static sagittal cervical spine. *Spine* 1996;21:667-75.
14. Pearson ND, Walmsley RP. Trial into the effects of repeated neck retractions in normal subjects. *Spine* 1995;20:1245-51.